

Injection Of Bone Marrow Concentrate For Bone Marrow Edema Lesions Provides Excellent Clinical Outcomes in Patients With Mild to Moderate Arthritis

Rajit Saluja, MD, Anand Saluja, Akshay Saluja, Eric Dorn, MD

Midwest Orthopedic Specialty Hospital, Franklin, WI

Introduction

- Bone Marrow Edema (BME) is a known cause of significant knee pain (1).
- Patients with osteoarthritis who have BME have been shown to have more pain and are more likely to progress to Total Knee Arthroplasty (3).
- Treatment of BME with non-biologic means has poor results and no healing of lesions (4,5,6).
- Injection of Bone Marrow Aspirate Concentrate (BMAC) with Demineralized Bone Matrix -Intraosseous Bioplasty (IOBP) has shown positive short-term results in some studies (7)
- The purpose of this study is to evaluate the clinical outcome of IOBP in the treatment of BME in patients undergoing arthroscopic meniscectomy and debridement with underlying mild to moderate osteoarthritis at a minimum two-year follow-up.

Methods and Materials

31 patients (13 males and 18 females, mean age 59.3 years (36-72-years) underwent IOBP for BME lesions concurrently with arthroscopic partial meniscectomy, debridement and had mild to moderate Osteoarthritis.

Kellgren-Lawrence Grading of Osteoarthritis:

- Grade 1: 3 patients
- Grade 2: 6 patients
- Grade 3: 12 patients
- Grade 4: 10 patients

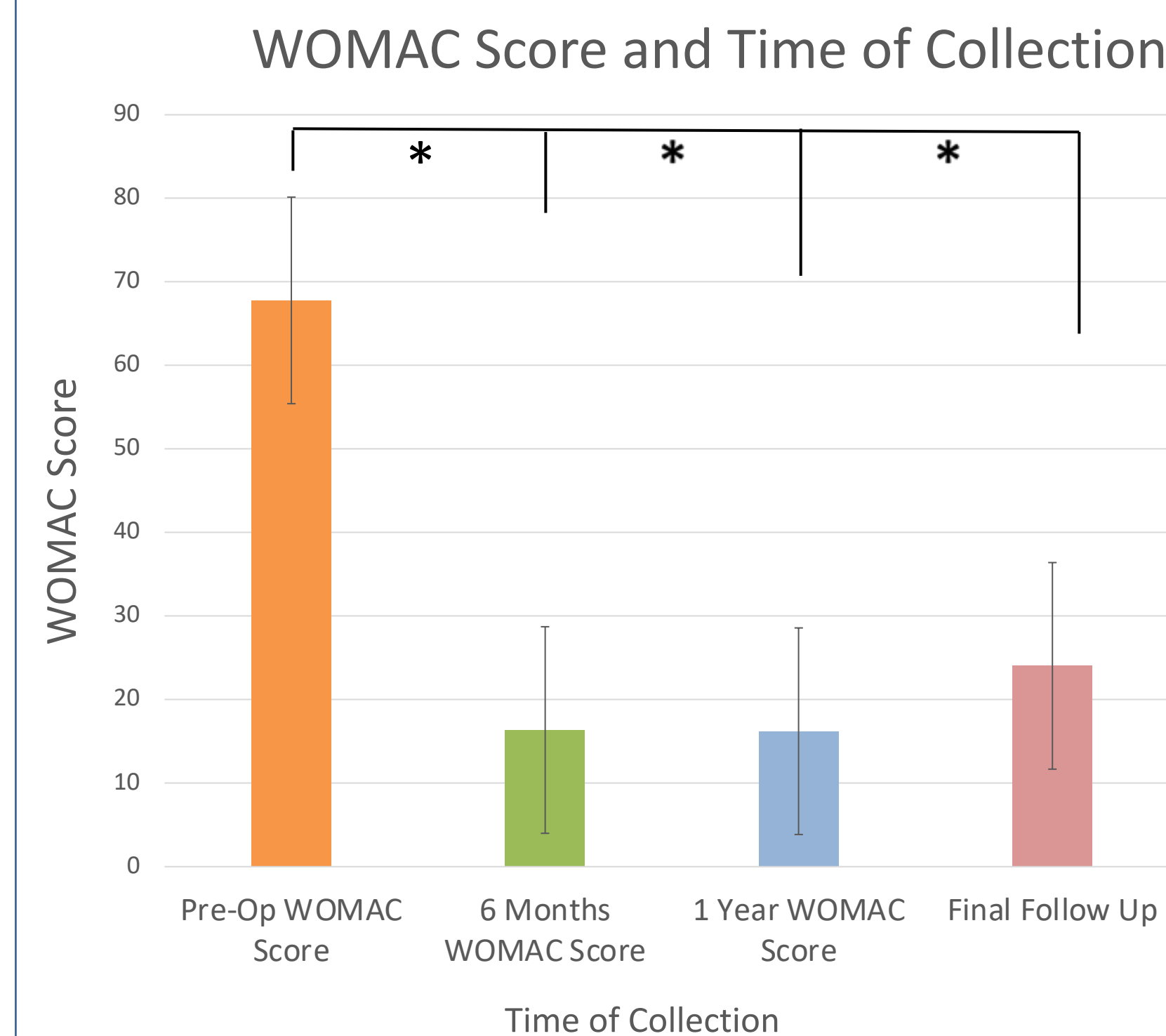
All patients had bone marrow aspiration from Posterior Superior Iliac Spine (PSIS), concentrated (Angel System, Arthrex, Naples, FL), and combined with demineralized bone matrix and injected into BME with fluoroscopic guidance following arthroscopic meniscectomy and debridement.

Clinical Outcome:

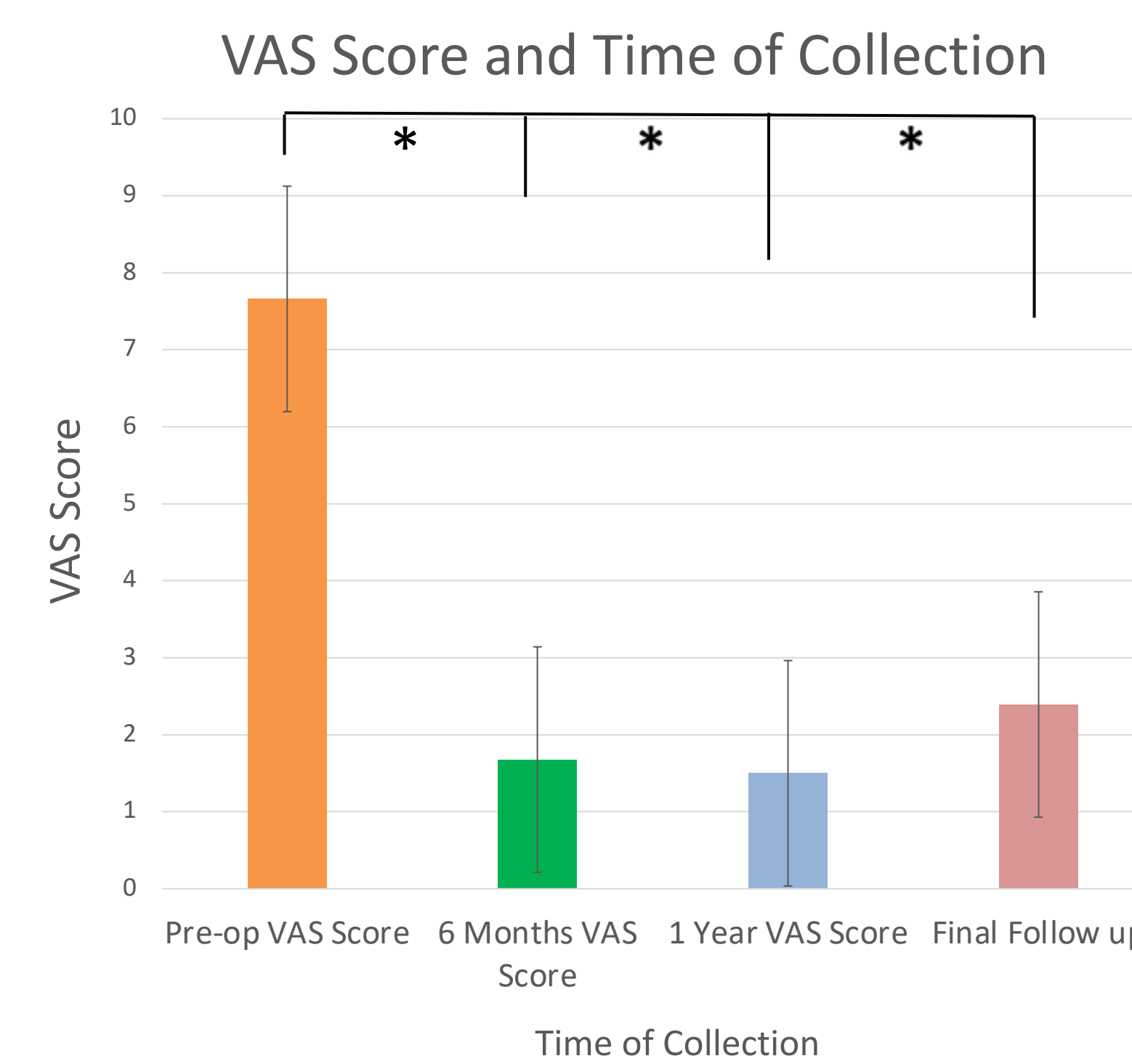
VAS Pain Scores and WOMAC Outcome Scores were taken Preop., 6 months post-op, 1-year post-op, and at the final follow-up.

Results

- Results show significant score reductions between preoperative WOMAC and VAS scores with scores taken 6 months post-op, 1-year post-op, and at the final follow-up
- 4/31 (13%) Patients underwent partial or total knee arthroplasty in first 2 yrs.
- 1/9 (11%) Patients with Kellgren-Lawrence Grade 1 or 2 OA underwent arthroplasty in first 2 yrs.
- 3/22 (14%) Patients with Kellgren-Lawrence Grade 3 or 4 OA underwent arthroplasty in first 2 yrs.



Graph 1: This graph depicts a comparison of the WOMAC Scores of patients in this study taken before their procedure, 6 months post-op, 1-year post-op, and at their final follow-up



Graph 2: This graph depicts a comparison of the VAS Scores of patients in this study taken before their procedure, 6 months post-op, 1-year post-op, and at their final follow-up

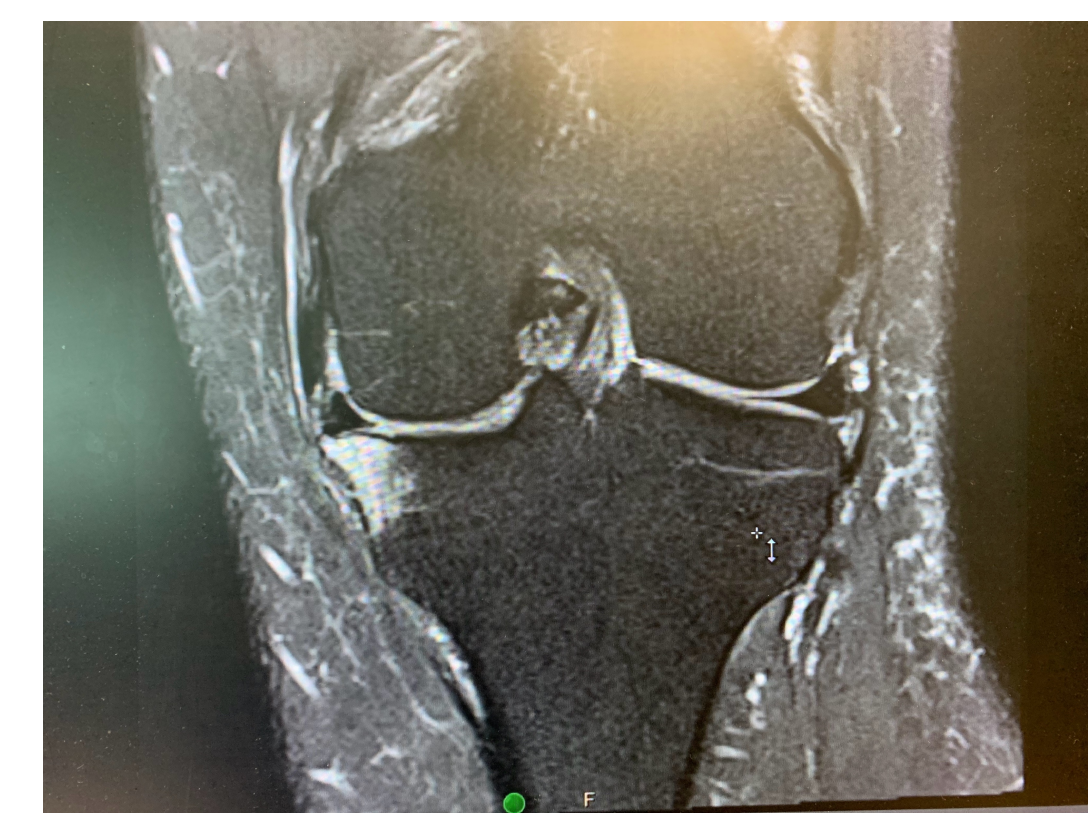

Figure 1: MRI image of BME from AP View- Case 1

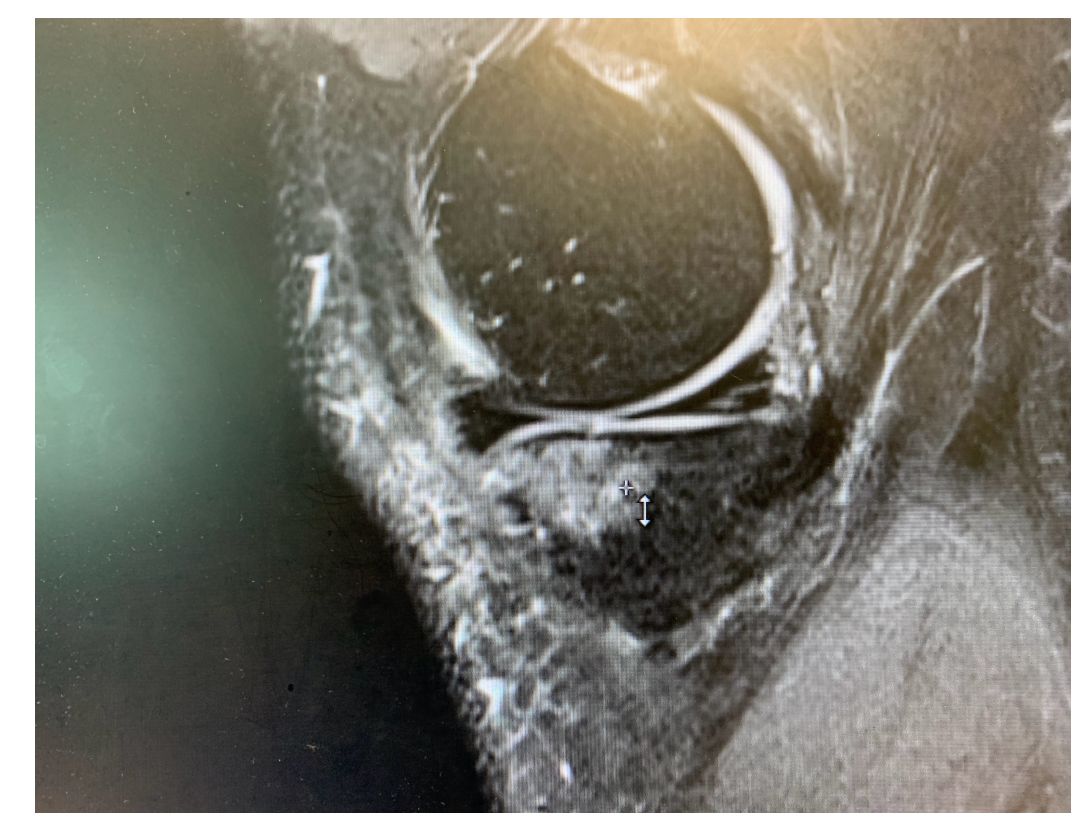


Figure 2: MRI image of BME from Lateral View- Case 1

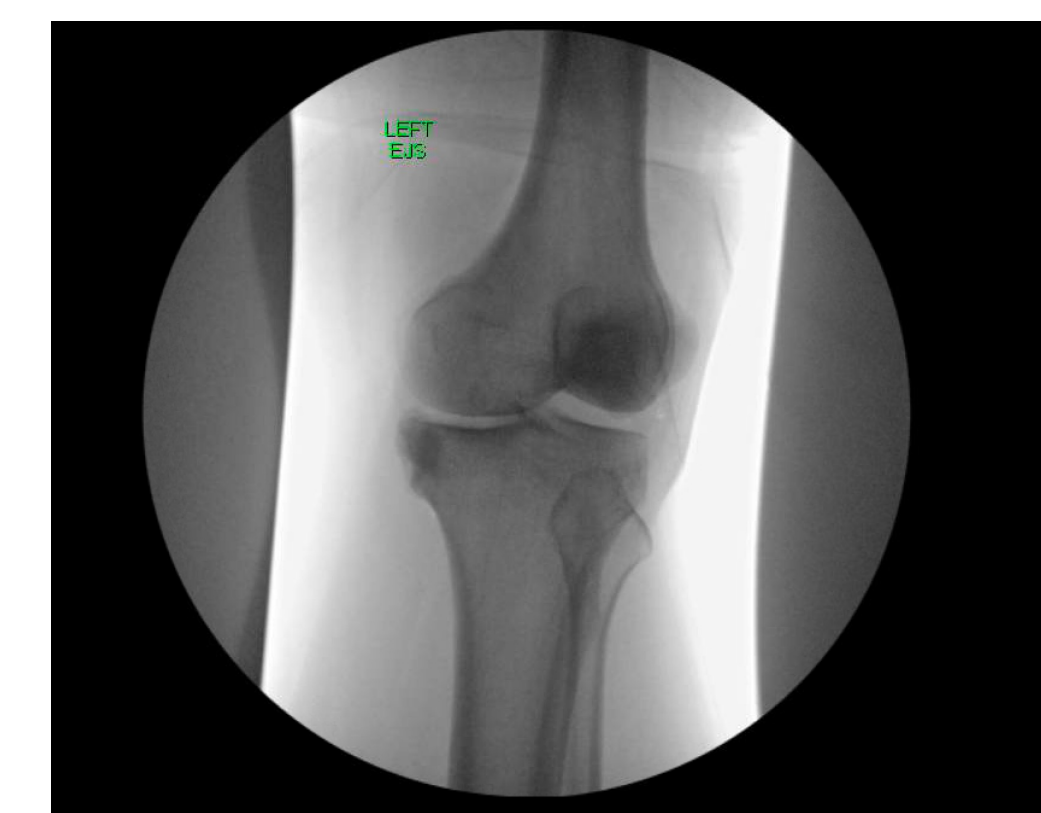

Figure 3: Intraoperative image of BME after completion of Bioplasty- Case 1

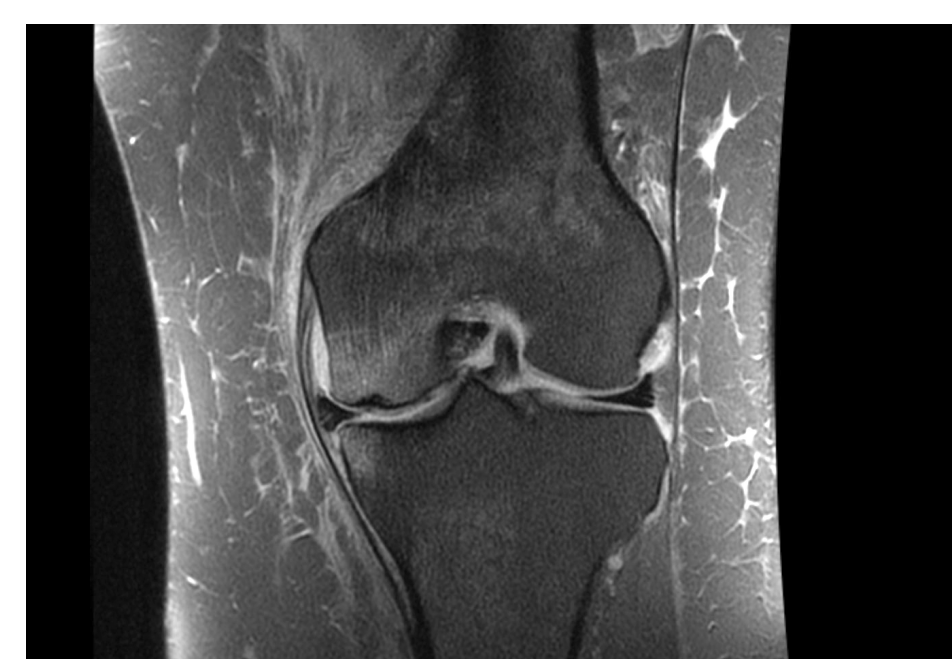

Figure 4: MRI Image of BME- Case 2

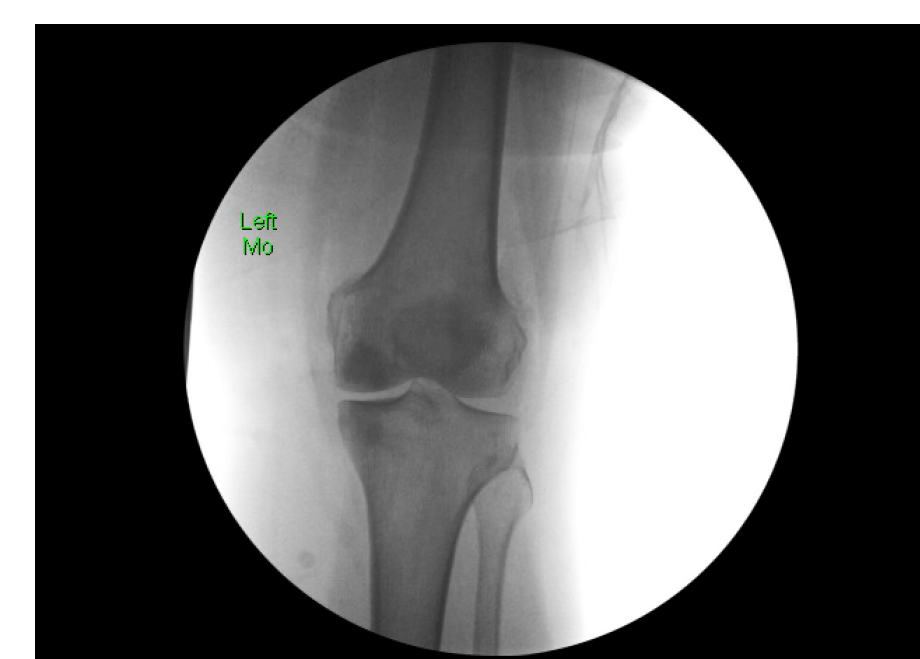


Figure 5: Intraoperative Image of BME post-Bioplasty- Case 2

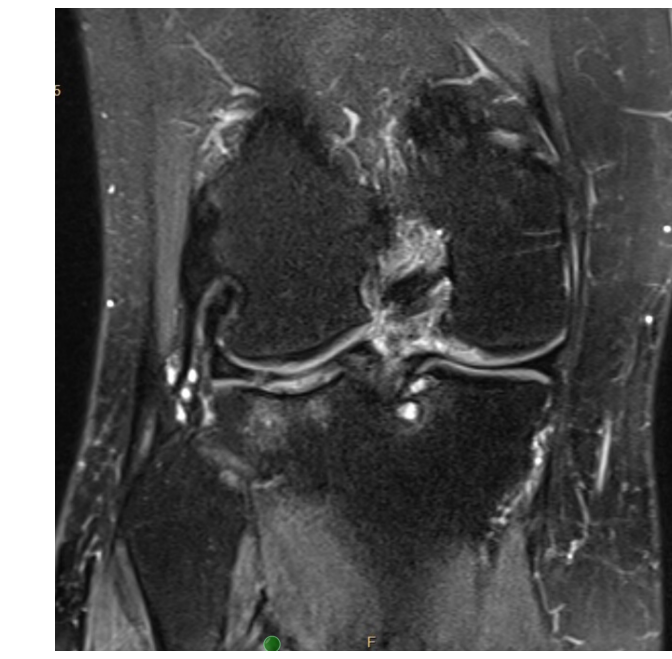


Figure 6: MRI Image of BME- Case 3

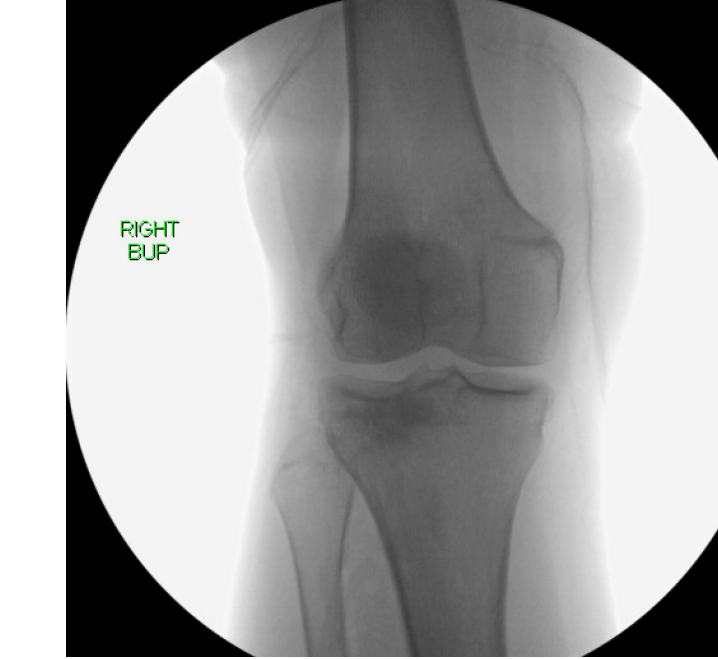


Figure 7- Intraoperative image of BME post-Bioplasty- Case 3



Figure 8: Bone marrow aspirate processing machine

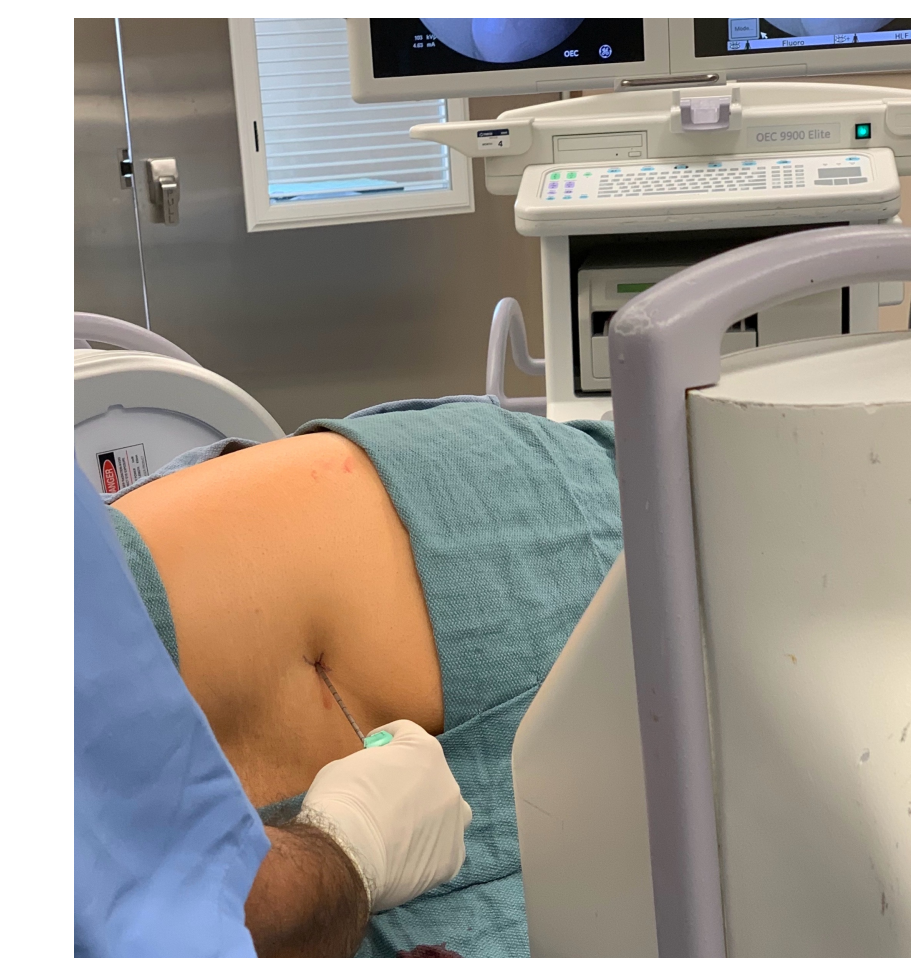

Figure 9: Technique to harvest the bone marrow using fluoroscopic guidance

Discussion

- Intraosseous Bioplasty treatment combined with arthroscopic partial meniscectomy shows improvement in pain and outcome scores which persists beyond 2 years even in patients with Grade 3 or 4 OA.
- Conversion rate to arthroplasty is 13% in the overall group and 14% in patients with Grade 3 or 4 OA.
- Studies of patients with similar pathology have shown that lack of durable pain relief following arthroscopic debridement alone (8) may be due to untreated BME lesions in those study groups.

References

1. Felson DT, Chaisson CE, Hill CL, et al. The association of bone marrow lesions with pain in knee osteoarthritis. *Ann Intern Med.* 2001; 134 (7): 541-549.
2. Roemer FW, Frobelt R, Hunter DJ, et al. MRI-detected subchondral bone marrow signal alterations of the knee joint: terminology, imaging appearance, relevance and radiological differential diagnosis. *Osteoarthritis Cartilage.* 2009; 17 (9): 1115-1131.
3. Tanamas SK, Wluka AE, Pelletier JP, et al. Bone marrow lesions in people with knee osteoarthritis predict progression of disease and joint replacement: a longitudinal study. *Rheumatology (Oxford).* 2010; 49 (12): 2413-2419.
4. Gomoll AH, Madry H, Knutsen G, et al. The subchondral bone in articular cartilage repair: current problems in the surgical management. *Knee Surg Sports Traumatol Arthrosc.* 2010; 18 (4): 434-447. doi: 10.1007/s00167-010-1051-8
5. Cavaignac E, Lafontan V, Reina N, Pailhé R. Failure of subchondroplasty for the treatment of knee pain associated with subchondral bone cysts. *Orthop Traumatol Surg Res.* 2013; 99 (12): 1239-1243. doi: 10.1016/j.otsr.2017.07.011
6. Belk JW, Kraeutler MJ, Houck DA, Goodrich JA, McCarty EC. Subchondroplasty for the treatment of knee pain and subchondral bone defects: a systematic review. *Arthroscopy.* 2018; 34 (6): 1999-2005. doi: 10.1016/j.arthro.2018.01.027
7. Kasik, CS, Martinkovich, S, Mosier, B, Akhavan, S. Short-Term Outcomes for the Biologic Treatment of Bone Marrow Edema of the Knee Using Bone Marrow Aspirate Concentrate and Injectable Demineralized Bone Matrix. *Arthroscopy, Sports Medicine, and Rehabilitation.* 2019; 1(1): e7-e14.
8. Thorlund JB, Juhl CB, et al., Arthroscopic surgery for degenerative knee: Systematic review and meta-analysis of benefits and harms. *BMJ* 2015; 350: h2747.